



**PATIENT**

Sydney Ziegler

**PRESENTING CLINICAL SIGNS**

History: Pre-op ECG showed VPCs.  
-CXR report: Mild cardiomegaly. No CHF.

**SPECIES**

Feline

**ECHOCARDIOGRAM FINDINGS**

2D, m-mode, color flow and doppler imaging is available. The left ventricular wall is normal in dimension. There is a diffusely hyperechoic endocardium consistent with fibrosis. The papillary muscles are mildly remodeled and hyperechoic. The endocardium also appears remodeled. The left atrium is normal in size. The right atrium is normal in size. The right ventricle appears normal. The mitral valve is normal in structure and mobility. Trace TR. Blood flow through both the LVOT and RVOT is normal in velocity. No pleural or pericardial effusion seen. No obvious cardiac tumors.

**BREED**

DSH

**SEX**

Female Spayed

**CARDIAC CHART**

**AGE**

9 years

**WEIGHT**

8.52lbs

**INTERPRETED BY**

Maggie Machen Lamy,  
DVM, DACVIM  
(Cardiology)

**IMAGING PERFORMED BY**

T. Tenorio, DVM

**HOSPITAL NAME**

Wauwatosa  
Veterinary

**REFERRING VET**

Dr. Binor

**INVOICE**

25265

**DATE**

7/12/22

FELINE CARDIAC PARAMETERS	BODY WEIGHT (kg)	HR (BPM)	IVSd (cm) (Moise, Pipers)	LVIDd (cm) (Moise, Pipers)	LWVd (cm) (Moise, Pipers)	FS (%)	EF (%)
NORMAL PARAMETER	-----	150-240	0.35-0.55	<2 (mean 1.5)	3.5-0.55	35-67	80-100
PATIENT	3.9	NM	0.4	1.38	0.4	53	87
FELINE CARDIAC PARAMETERS	LA/AO (Boon)	LA/AO HEART BASE (Swe) (Abbott)	LA 2D short axis Base view (cm) (Abbott)		LVOT VEL (m/s)	RVOT VEL (m/s)	E max (m/s)
NORMAL	<1.5	<1.3	<1.2		<1.6	<1.3	<0.9
PATIENT	1.4	1.2	1.0		0.93	0.84	NM

*\*Note: All measurements based upon multi-modal images and methods. An average value is reported.  
Adapted from June Boon, Veterinary Echocardiography, 1998  
Abbott J & MacLean H JVIM 2006;20: 111-119, Moise et al. Am J Vet Res 47:1476, 1986. Pipers et al. Am J Vet Res 40:882, 1979.*

**INTERPRETATION OF THE FINDINGS & FURTHER RECOMMENDATIONS**

Overtly normal cardiac dimensions and function. No LV hypertrophy or chamber dilation is identified. The LA is normal indicating low risk for complication. No additional issues are identified.

No cardiac cause for VPCs is seen in this study. Systemic/extra-cardiac causes should be considered in a senior cat. Full systemic evaluation is advised including abdominal ultrasound as indicated. Follow up/treatment for the arrhythmia should be dictated based upon the ECG report/evaluation.

No cardiac contraindication for general anesthesia from a structural standpoint. This does not address the arrhythmia which again should be dictated by the ECG report. Monitor for any development of clinical signs at home, including labored breathing, cough or signs of a blood clot (paralysis, neurologic change). No cardiac medications are clearly indicated.

A recheck echocardiogram is recommended in 12 months to screen for development of silent disease, sooner if a murmur, gallop or any respiratory signs are identified.



**PATIENT**

Sydney Ziegler

**SPECIES**

Feline

**BREED**

DSH

**SEX**

Female Spayed

**AGE**

9 years

**WEIGHT**

8.52lbs

**INTERPRETED BY**

Maggie Machen Lamy,  
DVM, DACVIM  
(Cardiology)

**IMAGING  
PERFORMED BY**

T. Tenorio, DVM

**HOSPITAL NAME**

Wauwatosa  
Veterinary

**REFERRING VET**

Dr. Binor

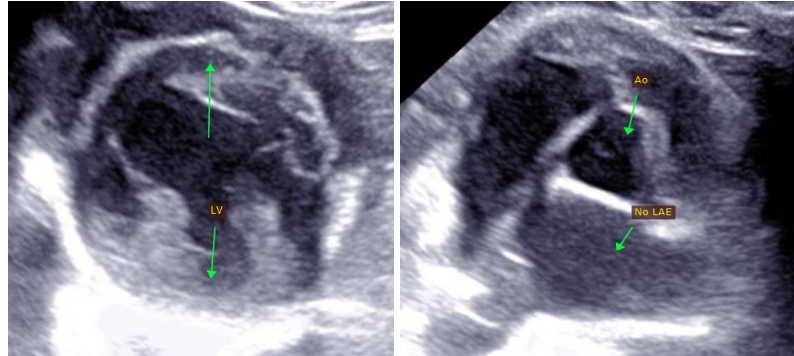
**INVOICE**

25265

**DATE**

7/12/22

**IMAGES**



The information and recommendations provided are based on the images presented by the referring veterinarian. No evaluation can be communicated regarding pathology that was not visible in the image/video clips provided.

Thank you for this referral. This report was generated using transcription software, and minor dictation errors may be present. If the clinical or image interpretation does not parallel your findings or if I can be of any further assistance, please contact me.

Maggie Machen Lamy, DVM  
Diplomate of the American College of Veterinary Internal Medicine (Cardiology)  
info@sonopath.com